

GINGER ATTENUATED DI (N-BUTYL) PHTHALATE-INDUCED REPRODUCTIVE TOXICITY IN PUBERTAL MALE RABBITS

ODA S.S.* , WAHEEB R.S.†

*Department of Pathology, Faculty of Veterinary Medicine, Alexandria University, EDFINA - BEHAIRA, Egypt.

†Department of Theriogenology, Faculty of Veterinary Medicine, Alexandria University , EDFINA - BEHAIRA, Egypt.

Abstract: This study was conducted to investigate the toxic effects of di (n-butyl) phthalate (DBP) on reproductive functions in male rabbits and the probable protective role of ginger. Twenty rabbits were divided equally into 4 groups: control group; DBP group (520 mg/kg body weight [BW] DBP orally), DBP+ginger group (520 mg/kg BW DBP and 400 mg/kg BW ginger) and ginger group (400 mg/kg BW ginger orally). Treatments were given three-times/week. After 7 wk of the experiment, DBP induced significant reduction in testis and prostate weights, serum and intratesticular testosterone concentrations, sperm counts both mass and progressive sperm motility and live sperms percentage as well as significant elevation of testicular malondialdehyde compared to control group. No significant changes were detected in epididymal weights, serum FSH and serum LH concentrations and testicular total superoxide dismutase and glutathione peroxidase activities in all treated groups. DBP induced considerable histopathological alterations in testis and to minimal extent in epididymis and prostates. Ginger treatment attenuated the significant changes to a certain extent induced by DBP intoxication in male rabbits probably due to its potential to scavenge free radicals.

Key Words: di (n-butyl) phthalate, ginger, rabbits, testes, prostate, semen quality.

INTRODUCTION

Phthalates (phthalate esters) are di alkyl or alkyl aryl esters of phthalic acid. Phthalates are synthetic plasticisers to improve product flexibility and durability. Plasticisers are mainly used as a part of building materials, home furniture, transportation, apparel, and to a restricted extent in wrapping of food and medical products (Niazi *et al.*, 2001). Phthalates are broadly disseminated in nature as a result of their assembling, use and transfer, as their residues enter the environment in the form of industrial sewage and effluents. They were found in the ecosystem at relatively high levels, resulting in environmental pollution (Niazi *et al.*, 2001). Di (n-butyl) phthalate (DBP) is one of the most widely studied phthalate esters that disturb the growth of normal reproductive organs. DBP is an endocrine disruptor, as it prevents the production and action of many hormones (O'Connor *et al.*, 2000; Shultz *et al.*, 2001). Additionally, DBP induced harmful effects on the male genital system in rabbits (Rihani *et al.*, 2015), human testicular dysgenesis syndrome (Mahood *et al.*, 2007) and rat phthalate syndrome, which is characterised by malformations in male genital organs, cryptorchidism, retention of nipples/areolae, and reduced anogenital distance (Lioy *et al.*, 2015). Several mechanisms have been reported to clear up the induction of testicular atrophy by DBP, such as the depletion of zinc (Park *et al.*, 2002), increased oxidative damage (Fukuoka *et al.*, 1990; Kasahara *et al.*, 2002; Erkekoglu *et al.*, 2010), alteration of vimentin cytoskeleton organisation (Kleymenova *et al.*, 2005), or membrane damage in Sertoli cells with concurrent sloughing of spermatogenic cells (Kleymenova *et al.*, 2005). A recent study demonstrated that high doses of DBP induced apoptosis in various spermatogenic cells (Ünal *et al.*, 2016). Oxidative stress occurs due to an imbalance between the excessive formation of reactive oxygen species (ROS) and imperfect antioxidant defences.

Correspondence: S. S. Oda, samahoda@yahoo.com. Received April 2017 - Accepted June 2017.
<https://doi.org/10.4995/wrs.2017.7466>

As a result of high polyunsaturated fat content in spermatozoa membranes, they are highly susceptible to oxidative stress induced damage (Kumar *et al.*, 2006). The main possible mechanism of toxicity is based on the oxidative stress (Zhou *et al.*, 2010). Several studies reported that DBP induced lipid peroxidation in rat testis (Wang *et al.*, 2004 and Nair, 2015).

Antioxidants play an important role in scavenging the damaging effect of free radicals in human and animals (Noori, 2012). A lot of natural products have protective effects against different medication or chemically-provoked toxicities (Mansour *et al.*, 2012; Hosseinimehr, 2014; Baiomy and Mansour, 2015). Ginger (*Zingiber officinale* Roscoe, Zingiberaceae) is used worldwide as a spice and an alternative medical treatment. Ginger has potential for use in the prevention and treatment of numerous diseases through modulation of biological activities (Rahmani *et al.*, 2014). Additionally, ginger's antioxidative (Khaki *et al.*, 2009; Riaz *et al.*, 2011) and androgenic properties (Kirtikar and Basu, 1991; Riaz *et al.*, 2011) have been reported in animal models. Ginger as an antioxidant agent has the ability to scavenge free radicals and protect the cells from lipid oxidation (Farag *et al.*, 2010). Many studies have stated that ginger exerted a protective role against male reproductive dysfunction (Zahedi *et al.*, 2010; Bordbar *et al.*, 2013; Aghaie *et al.*, 2015). The antioxidative constituents of *Z. officinale* (6-gingerol and its derivatives) could enhance numerous sperm characteristics, for example, count and viability (Hafez, 2010).

Hence, the main aim of this work was to investigate the possible protective impact of ginger against DBP-induced alterations of male reproductive functions in rabbits.

MATERIALS AND METHODS

Animals and treatment

Adult male rabbits aged 6-6.5 mo, weighing 3000-3500 g body weight (BW), were purchased from Faculty of Agriculture, Alexandria University. Rabbits were kept in metal cages in Pathology Department, Faculty of Veterinary Medicine, Alexandria University. Animals were fed pelleted commercial diet (88% dry matter, 23% crude protein, 15% crude cellulose, 8% crude ash, 1% calcium, 0.9% phosphorus, 0.5% sodium, 1.0% NaCl, 0.6% methionine) and had free access to water. Rabbits were adapted and kept under observation for 2 wk prior to the beginning of the experiment. Twenty rabbits were distributed equally into 4 groups (5 each): the first group was control (received 1 mL distilled water and 1 mL olive oil via stomach tube); the second group consisted of DBP-treated rabbits receiving 520 mg/kg BW di-n-butyl phthalate (Sigma Aldrich, USA). The dose of DBP was designed in rat by Paget and Barnes (1964). The third group was DBP+ginger-treated rabbits receiving 520 mg/kg BW DBP and 400 mg/kg BW ginger simultaneously. The fourth group was ginger-treated rabbits receiving 400 mg/kg BW ginger. Ginger was purchased from Mepaco-Medi food Company (Sharkeya, Egypt). The ginger dose was selected to be used for rabbits according to Baiomy and Mansour (2015). Treatments were applied orally by stomach tube, three times weekly for 7 wk (to cover the whole spermatogenic cycle period in rabbits). Rabbits received humane care in consistence with the animal care rules of the National Institute of Health. This study was permitted by the Scientific Research Ethics Committee, Faculty of Veterinary Medicine, Alexandria University.

Evaluation parameters

Body and reproductive organs weight changes

At the beginning of the experiment, all rabbits were ranked by equalising their initial body weights between all groups. Rabbits were weighed weekly until the end. After 7 wk, all rabbits were euthanised. Testes, epididymis and prostate (including 3 parts: proprostate, prostate, paraprostate) glands were collected for careful gross examination and weighed. In addition, an index weight (IW) of each organ=organ weight (g)/BW (g)×100 was calculated (Matousek, 1969).

Serum hormones assay

Blood samples were collected from ear veins of all the rabbits during the 4th and 7th wk (before euthanasia) and kept at room temperature for 15 min for blood clotting, then centrifuged at 3000 rpm for 10 min. Then, the obtained sera

were kept at -20°C until use. Serum was separated for estimation of follicle stimulating hormone (FSH) and luteinising hormone (LH) using competitive immunoassay technique (Rat ELISA kit: E12654r (LH), E06869r (FSH), CUSABIO, China). Intra-assay coefficient of variation (CV) was $<15\%$. Briefly, $50\ \mu\text{L}$ of sample/standard was incubated for 1 h with equal volume of antibody specific for LH/FSH and HRP-conjugate provided with the kit in a pre-coated assay plate. The plate then was washed twice and reaction was revealed using chromogenic substrate; optical density was then measured by microplate reader at 450 nm (Sharma *et al.*, 2011). Serum testosterone levels were measured using competitive immunoassay technique (Rat ELISA kit: 55-TESTMS-E01, ALPCO Diagnostics, USA). Intra-assay CV was $<15\%$ and sensitivity of the kit was $0.066\ \text{ng/mL}$. The assay was performed by incubating $10\ \mu\text{L}$ of sample/standard with $100\ \mu\text{L}$ of incubation buffer and $50\ \mu\text{L}$ of enzyme-conjugate in a pre-coated assay plate. After washing, reaction was revealed using chromogenic substrate; optical density was then measured by microplate reader at 450 nm. Samples were run in one assay, eliminating inter-assay variability.

Estimation of testicular oxidative stress, antioxidant enzymes and testosterone levels

After euthanasia of all rabbits, one testis was collected from each animal and kept frozen at -70°C until analysis. One gram of testis was homogenised in 9 volumes of phosphate buffer saline and then centrifuged at 3000 rpm for 15 min. The supernatant was separated off and used for assessment of lipid peroxidation (LPO) content. LPO was evaluated as malondialdehyde (MDA) and measured spectrophotometrically based on the reaction with thiobarbituric, following the technique described by Placer *et al.* (1966). Glutathione peroxidase (GPx) activity was measured in the testicular tissue using the technique stated by Paglia and Valentine (1967). Determination of testicular total superoxide dismutase (SOD) was performed according to the method described by Marklund and Marklund (1974). LPO, GPx and SOD were estimated using commercial kits purchased from Bio-diagnostics Company, Cairo, Egypt. Intratesticular testosterone (ITT) was estimated according to Demetriou (1987) using competitive immunoassay technique (Rat ELISA kit: 55-TESTMS-E01, ALPCO Diagnostics, USA). Intra-assay CV was $<15\%$ and sensitivity of the kit was $0.066\ \text{ng/mL}$. The assay was performed by incubating $10\ \mu\text{L}$ of sample/standard with $100\ \mu\text{L}$ of incubation buffer and $50\ \mu\text{L}$ of enzyme-conjugate in a pre-coated assay plate. After washing, reaction was revealed using chromogenic substrate; optical density was then measured by microplate reader at 450 nm. Samples were run in one assay, eliminating inter-assay variability.

Semen collection and sperm characteristics

The right and left epididymis were squeezed gently to avoid morphological lesions from the caudal part of the epididymis on a pre-warmed slide for evaluation of mass motility at magnification ($100\times$). Three fields were examined by the same person based on mass motility scoring system: Zero: no observed motility; 1: wave absent but sperm movements seen at different areas; 2: slow wave formation, 3: wave formation with good velocity; 4: waves with swirls formation. Twenty μL of collected semen was aspirated and diluted with 2.9% sodium buffered citrate and used for evaluating progressive motility at magnification ($400\times$) of 3 fields by the same person on a scale of 0 to 100%.

Sperm count

Fresh semen samples were used to assess the concentration of sperm (million/mL) using a haemocytometer as described by Bearden and Fuquay (1980). A small drop was placed on a warm clean glass slide. A cover slip was placed over the semen droplet. The obtained sperm count in 5 squares was multiplied by 10000 to get the number per mL.

Live sperm percent

Live spermatozoa percentage was determined. A semen drop from each animal was mixed with a drop of eosin-nigrosin stain. A thin film was spread onto a clean slide. Two hundred sperms were examined per each slide at magnification ($400\times$) according to Bearden and Fuquay (1980).

Histopathological examination

Shortly after rabbits' euthanasia reproductive organs were weighed, one testis randomly selected, epididymis and prostates from each rabbit were preserved in 10% neutral buffered formalin for at least 24 h. Tissue specimens were dehydrated, cleared, embedded in paraffin, sectioned and stained with haematoxylin and eosin (HE).

Statistical analysis

Data analyses were carried out using SAS (Statistical Analysis System software version 9.1, SAS Institute Inc., Cary, NC, USA). Repeated measures analysis of variance (RM-ANOVA) was used to analyse data with multiple measurements per animal using the MIXED Procedure of SAS with the PDIFF option to compare means. For data that were measured only once, one-way ANOVA (the GLM Procedure, SAS) was performed to detect group differences, followed by Duncan's Multiple Range Test for separate means. Semen data expressed as percentage (progressive motility and live sperm) were arcsine-transformed, and sperm concentration was log₁₀-transformed prior to analysis. Before running the analyses, groups were assessed for homogeneity of variances and normality. Nonparametric Kruskal-Wallis test, followed by Dunn's post-hoc test (NPAR1WAY procedure, SAS), was applied to ordinal data (sperm mass motility score), as well as on variables that did not satisfy the assumptions of ANOVA. Probability values less than or equal to 0.05 were considered significant. Data are expressed as mean±standard error of the mean (SE).

RESULTS

No significant changes ($P>0.05$) occurred in BW of rabbits treated with DBP, DBP+ginger and ginger all over the experimental period compared to control rabbits (Figure 1) with a mean of 3115±118 g at start and 3118±152 g at the end.

Reproductive organs weight results

A significant decrease ($P<0.05$) was noticed in testes weights and testes index weights in the DBP-treated group compared to control (Table 1). Moreover, epididymis and prostate weights and their index weights in all treated groups showed non-significant alterations ($P>0.05$) when compared to control.

Serum reproductive hormones assays

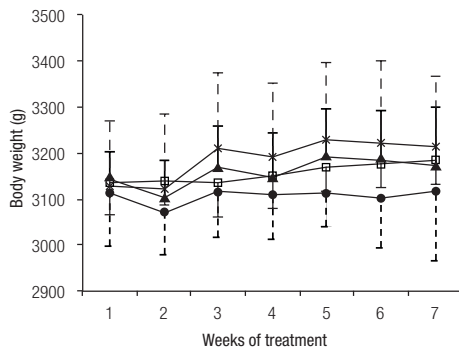


Figure 1: Effect of di-n-butyl phthalate (DBP) and ginger on the body weight (g) of male rabbits. Values are means and standard errors. For easier visualisation, minus error bars are used for control and DBP groups, and plus bars for DBP+ginger and ginger groups. Group means do not differ significantly ($P>0.05$) within all periods. ●— control; □— DBP; ▲— DBP+ginger; ×— ginger.

During the 4th and 7th wk of the experiment, the serum testosterone levels exhibited a significant decrease ($P<0.05$) in the DBP- and DBP+ginger-treated groups. However, a sharp decrease was found in the DBP-treated group (Table 2). A non-significant difference ($P>0.05$) in serum levels of both LH and FSH was observed among all treatment groups at the 2 time points of assessment compared to the control group.

Testicular oxidative stress, antioxidant enzymes and testosterone levels

A significant elevation ($P<0.05$) was recorded in the levels of testicular MDA in DBP-treated group in comparison to control (Table 3). However, testicular GPx and SOD levels showed non-significant change ($P>0.05$) in all treatment groups in comparison to control. Moreover, a significant decrease in ITT levels was reported in DBP- and DBP+ginger-treated groups compared to control group, but a noticeable decline also occurred in the former (Table 3).

Table 1: Effect of di-n-butyl phthalate (DBP) and ginger on absolute and relative weight of reproductive organs of male rabbits.

	Group			
	Control	DBP	DBP + Ginger	Ginger
Testes weight (g)	8.41±0.30 ^b	7.41±0.28 ^a	8.45±0.16 ^b	8.35±0.09 ^b
Testes IW	0.27±0.014 ^b	0.23±0.009 ^a	0.27±0.008 ^{ab}	0.26±0.014 ^{ab}
Epididymis weight (g)	2.11±0.19	1.85±0.10	2.11±0.10	2.04±0.09
Epididymis IW	0.07±0.003	0.06±0.003	0.07±0.002	0.06±0.002
Prostate weight (g)	4.88±0.50 ^{ab}	3.74±0.46 ^a	4.86±0.25 ^{ab}	6.81±1.60 ^b
Prostate IW	0.16±0.02 ^{ab}	0.12±0.01 ^a	0.15±0.01 ^{ab}	0.21±0.04 ^b

Values are means±standard errors.

Means in a row without a common letter differ significantly ($P<0.05$).

IW (Index weight)=organ weight (g)/body weight (g)×100.

Semen assessment and sperm qualities

Both mass and progressive sperm motility were significantly decreased ($P<0.05$) in DBP-treated rabbits compared to controls (Table 4). Sperm count exhibited a significant reduction ($P<0.05$) in DBP-treated rabbits and a non-significant difference in DBP+ginger- and ginger-treated groups when compared to control (Table 4). Likewise, live sperms percentage showed a significant decrease ($P<0.05$) in DBP-treated group and a non-significant alteration ($P>0.05$) in the ginger-treated groups in comparison to control (Table 4).

Histopathological examination

Testis

Testicular sections of control and ginger-treated rabbits showed regular arrangement of the seminiferous tubules with various spermatogenic stages and normal interstitial tissue, including Leydig cells and blood vessels (Figure 2a, 2b). DBP-intoxicated rabbits showed shrunken, degenerated and necrotic hyalinised seminiferous tubules (Figure 3a). Irregularly shaped and sized seminiferous tubules showed disorganised attenuated spermatogenic cells, reduction in spermatids and sperm production with widening of their lumen (Figure 3b). Some tubules exhibited desquamation of the necrotic spermatogenic cells with formation of giant cells (Figure 3c). There were interstitial oedema and Leydig cells hyperplasia (Figure 3d) at different places. Rabbits from the DBP+ginger-treated group had nearly uniform rounded seminiferous tubules with different spermatogenic stages, including spermatids and spermatozoa (Figure 4a). However, some tubules had desquamated germinal epithelium with giant cell formation in their lumina (Figure 4b). Mild congestion and mild interstitial oedema were present.

Table 2: Effect of di-n-butyl phthalate (DBP) and ginger on the serum hormone levels of male rabbits.

	Week	Group			
		Control	DBP	DBP + Ginger	Ginger
Serum testosterone (ng/mL)	4	3.19±0.32 ^b	1.36±0.22 ^a	1.48±0.08 ^a	2.86±0.34 ^b
	7	3.58±0.99 ^b	2.06±0.61 ^a	2.14±0.63 ^a	2.79±0.82 ^b
Serum LH (pg/mL)	4	4.00±0.04	4.91±0.29	4.58±0.36	4.46±0.12
	7	4.62±0.04	5.21±0.72	5.12±0.81	4.08±0.13
Serum FSH (pg/mL)	4	8.95±0.33	9.71±0.43	9.32±0.96	8.37±0.61
	7	8.44±0.37	9.33±0.76	9.22±0.33	8.47±0.75

Values are means±standard errors.

Means in a row without a common letter differ significantly ($P<0.05$).

Table 3: Effect of di-n-butyl phthalate (DBP) and ginger on the testicular peroxidation markers and testicular testosterone level of male rabbits.

	Group			
	Control	DBP	DBP + Ginger	Ginger
MDA (nmol/g)	1.44±0.19 ^a	2.54±0.14 ^b	1.65±0.10 ^a	1.61±0.11 ^a
GPx (IU)	14.92±2.41	12.46±0.89	13.63±1.09	13.94±0.55
SOD (IU/mg)	1.69±0.01	1.66±0.01	1.70±0.01	1.67±0.03
Testosterone (ng/mg)	24.85±0.16 ^b	22.87±0.33 ^a	23.81±0.32 ^a	24.79±0.14 ^b

Values are means±standard errors.

Means in a row without a common letter differ significantly ($P<0.05$).

MDA, Malondialdehyde; GPx, Glutathione peroxidase; SOD, superoxide dismutase.

Epididymis

Epididymal histoarchitecture of control (Figure 5a, 5e, 5i) and ginger-treated (Figure 5b, 5f, 5j) rabbits was nearly normal and epididymal ductal lumina were packed with sperms. Some of epididymal ductules of the DBP-intoxicated rabbits were free of sperms and others contained minimal to moderate compactness of sperms with desquamated germinal cells (Figure 5c, 5g, 5k). Epididymis of the DBP+ginger-treated rabbits exhibited normal histologic structure and normal sperm density (Figure 5d, h, l).

Prostate gland

Prostate gland of the control and the ginger-treated rabbits was histologically normal, with presence of copious amount of glandular secretions (Figure 6a, 6b). However, prostate of the DBP-intoxicated rabbits showed interstitial congestion and oedema as well as reduction of the glandular secretion (Figure 6c). Treatment of DBP-intoxicated rabbits with ginger caused dilatation of tubuloalveolar glandular structures with eosinophilic secretions (Figure 6d).

DISCUSSION

Regardless of the fact that the level of DBP exposure is limited, it is considered that this water and soil toxicant provokes acute and chronic toxicity against various living organisms (Graham, 1973; Mylchreest *et al.*, 2000). Moreover, excessive exposure to ROS is one of the main reasons of male infertility. Phthalates are one of many damaging factors that affect fertility. Earlier studies indicated that phthalates induced testicular atrophy in laboratory animals (Oishi and Hiraga, 1980), increased ROS production in the testes of rats and induced spermatocyte apoptosis (Únal *et al.*, 2016). The present study demonstrated that all treated groups showed no significant difference in body weights throughout the experimental period. Similar results were documented by Głombik *et al.*, (2014). However, our study revealed that DBP treatment of rabbits for 7 wk exerted a significant elevation ($P<0.05$) in the testicular MDA levels. MDA is a final product of lipid peroxidation and a marker of oxidative stress which hinders protein biosynthesis in the cell (Doreswamy *et al.*, 2004). However, there were non-significant changes in the values of testicular GPx and SOD. This may be explained by using the low toxic dose of the DBP (520 mg/kg BW rabbit). Thus, Nair (2015) reported that rats treated 7 d with DBP at dose 500 mg/kg BW exhibited a non-significant reduction in testicular GPx levels, but

Table 4: Effect of di-n-butyl phthalate (DBP) and ginger on the sperm characteristics of male rabbits.

	Group			
	Control	DBP	DBP + Ginger	Ginger
Mass motility score	3.60±0.24 ^b	1.00±0.32 ^a	3.20±0.49 ^{ab}	3.40±0.25 ^b
Progressive motility (%)	88.0±1.7 ^b	10.0±5.2 ^a	79.0±5.3 ^b	83.0±3.0 ^b
Sperm count ×10 ⁶ /mL	183.4±12.5 ^b	88.6±21.6 ^a	169.6±31.2 ^b	184.6±22.0 ^b
Live sperm (%)	88.6±3.3 ^b	3.0±0.7 ^a	87.6±2.8 ^b	88.4±2.4 ^b

Values are means±standard errors.

Means in a row without a common letter differ significantly ($P<0.05$).

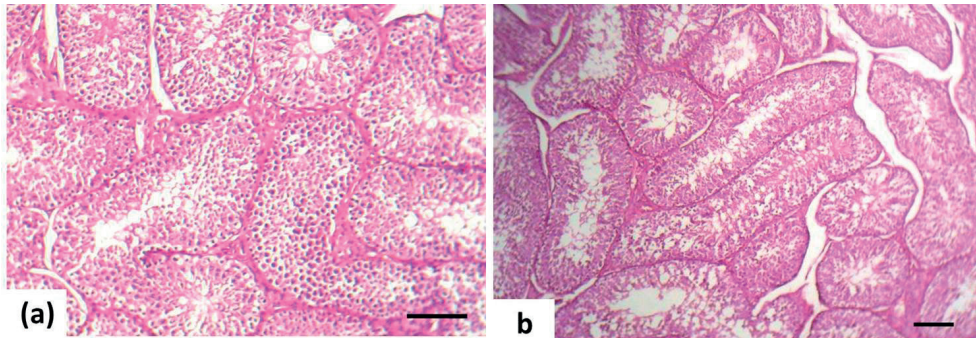


Figure 2: Rabbit testes stained by haematoxylin and eosin (Bar=100 μ). Control rabbit (a) and ginger treated rabbit (b). Regular arrangement of the seminiferous tubules with various spermatogenic stages and normal interstitial tissue.

it increased significantly at doses of 1000 and 1500 mg/kg BW. The balance between ROS and antioxidant enzymes in the male reproductive system is crucial for sperm health and survival. Hence, ginger was used in this study to evaluate its antioxidative (Khaki *et al.*, 2009; Riaz *et al.*, 2011) and androgenic properties (Kirtikar and Basu, 1991; Riaz *et al.*, 2011) against DBP-induced reproductive toxicity in male rabbits. The DBP+ginger-treated group showed non-significant changes in testicular MDA, GPx and SOD. Our study confirmed that DBP had negative effects on the

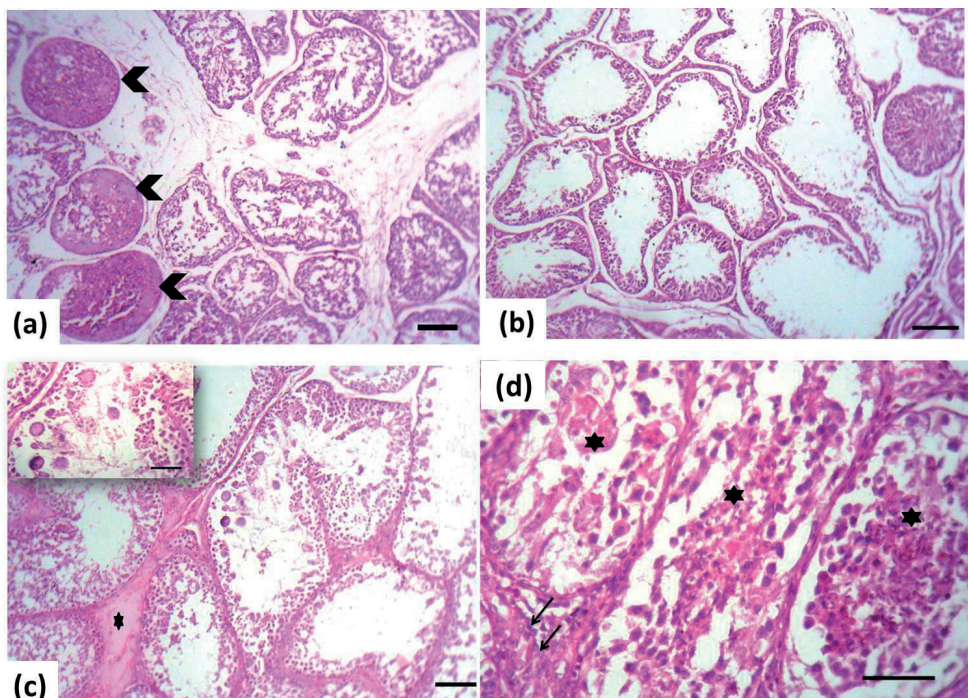


Figure 3: Testes of a rabbit treated with di-n-butyl phthalate stained by haematoxylin and eosin (bar=100 μ). (a) Shrunken degenerated and necrotic hyalinised (arrowheads) seminiferous tubules; (b) Disorganised attenuated spermatogenic cells, reduction in spermatogenesis with widening of their lumen; (c) Desquamation of the necrotic spermatogenic cells with giant cells formation (inset, bar=50 μ) and interstitial oedema (asterisk); (d) Necrotic seminiferous tubules (asterisks) with Leydig cells hyperplasia (arrows) (Bar=50 μ).

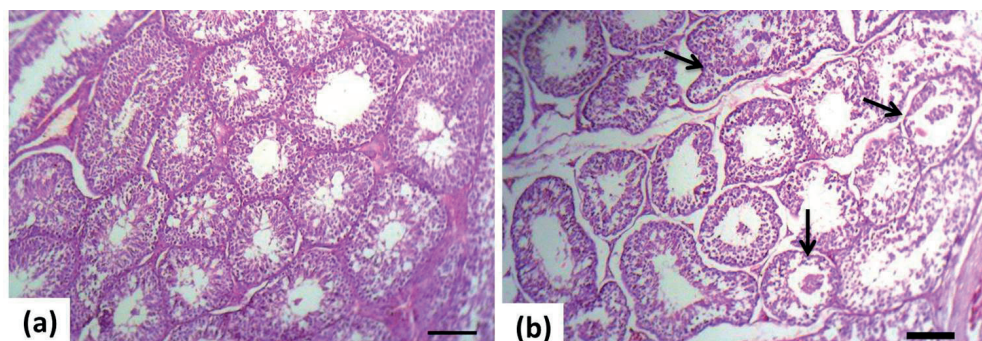


Figure 4: Testes of a rabbit treated with di-n-butyl phthalate and ginger stained by haematoxylin and eosin (bar=100 μ). (a) Uniform rounded seminiferous tubules with different spermatogenic stages including spermatids and spermatozoa; (b) Some tubules had desquamated germinal epithelium with giant cells formation in their lumina (arrows).

reproductive organ weights, testes and prostate weights and their index weights, but epididymis weights showed non-significant difference compared to control. Treatment with ginger showed non-significant changes on the reproductive organs weights and their index. Regarding sperm characteristics, DBP decreased both mass and progressive sperm motility and live sperm percentage. Cytoplasmic membrane of sperm cells is rich in polyunsaturated fatty acids, which can easily undergo peroxidation by ROS, which lessens their motility and increases mortality. The increase in ROS generation lessens sperm motility by impairing the flagellar axonemal structure and consequently hinders forward progressive sperm motility (El-Taieb *et al.*, 2009). These findings were parallel to those described by Farombi

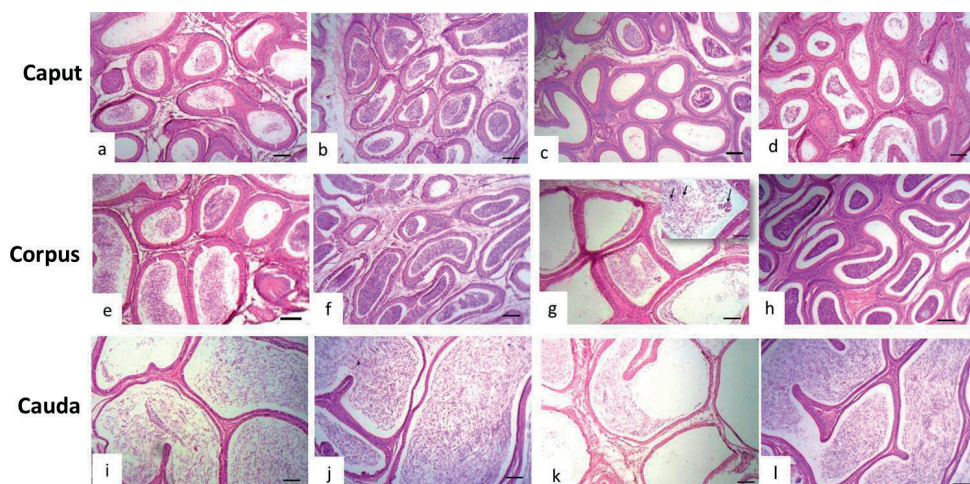


Figure 5: Epididymis of a rabbit stained by haematoxylin and eosin (Bar=100 μ). (a, e, i) Control rabbit. (b, f, j) Ginger-treated rabbit had normal histoarchitecture with normal sperm compactness. (c, g, k) Epididymal ductules of a di-n-butyl phthalate intoxicated rabbit contained minimal to moderate sperm compactness with desquamated spermatogenic cells (arrows) (inset, Bar=50 μ). (d, h, l) Epididymis of a di-n-butyl phthalate intoxicated +ginger-treated rabbit exhibited normal histologic structure and normal sperm density.

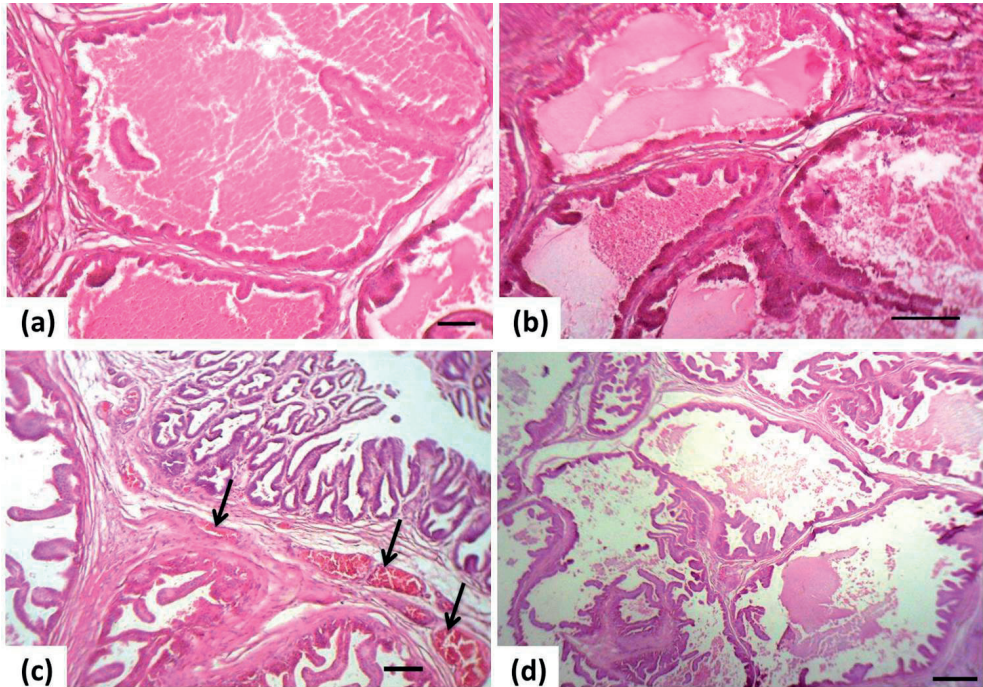


Figure 6: Prostate of a rabbit stained by haematoxylin and eosin (Bar=100 μ). (a) Control rabbit and (b) ginger-treated rabbit had normal histoarchitecture with presence of copious amount of glandular secretion. (c) A di-n-butyl phthalate intoxicated rabbit showed interstitial congestion (arrows) with reduction of the glandular secretion. (d) A di-n-butyl phthalate intoxicated+ginger-treated rabbit exhibited dilatation of tubuloalveolar glandular structures with eosinophilic secretions.

et al., (2007). DBP induced significant reduction in the sperm count of treated rabbits. Ginger treatment ameliorated the semen quality parameters compared to those of the control rabbits. The anti-androgenic effect of phthalates is mainly triggered by interfering testosterone synthesis, in contrast to other anti-androgens which directly react with the androgen receptor (Thompson *et al.*, 2004; Gray *et al.*, 2006). Moreover, phthalates downregulate the expression of genes required in cholesterol conveyance and testosterone synthesis in male rats (Thompson *et al.*, 2005; Borch *et al.*, 2006). Parallel to this, our results showed that DBP treatment reduced the serum (Nair *et al.*, 2008; Nair, 2015) and testicular testosterone levels. Non-significant changes in the serum levels of LH and FSH were recorded during the 2 time points of study. This could be attributed to the reduction in testosterone levels and consequently the transient increment in the level of LH through feedback mechanism until LH stimulate Leydig cells to secrete testosterone (Pan *et al.*, 2006). Moreover, the toxic substances that impair the function of Leydig cells result in a decline in testosterone secretion, and in consequence can disrupt spermatogenesis. Even though testicular testosterone secreted under LH motivation may sustain spermatogenesis, it is well known that the mutual effect of FSH and LH is necessary for maximum spermatogenesis (reviewed in Pan *et al.*, [2006]). Unlike the previous studies (Kirtikar and Basu, 1991; Riaz *et al.*, 2011) that reported the androgenic properties of ginger, our study revealed that ginger treatment failed to improve the serum and testicular testosterone levels compared to control rabbits. However, no significant alterations were found in the serum levels of both LH and FSH in DBP+ginger-treated rabbits. Histopathological findings in the testis of rabbits treated with DBP consisted of various degenerative changes. Irregular small-sized seminiferous tubules showed disorganised attenuated spermatogenic cells, reduction in spermatids and sperm production and desquamation of the necrotic spermatogenic cells with giant cells formation. Interstitial oedema and Leydig cells hyperplasia were prominent. These findings were comparable to those described by Alam *et al.*, (2010) and Bao

et al., (2011). Nair *et al.* (2008) and Nair (2015) stated similar histopathological results, although they reported atrophy of Leydig cells. Testicular lesions could be ascribed to the rise in MDA production and the resultant lipid peroxidation with advanced reduction in the various spermatogenic cells, as well as degeneration of Sertoli and Leydig cells. Ginger treatment ameliorated the histopathologic lesions induced by DBP as the seminiferous tubules were uniform, rounded with different spermatogenic stages including spermatids and spermatozoa. However, some tubules had desquamated germinal epithelium along with formation of giant cells in their lumina, with mild interstitial oedema and congestion. The histopathologic alterations of epididymis and prostates of DBP-treated rabbits were of lesser extent than that found in the testis, as testis is the main target organ for DBP reproductive toxicity in rodents; however, treatment of ginger improved these subtle changes. The amelioration in the histoarchitecture of testes, epididymis and prostates was related to the vital role of ginger in controlling ROS produced by DBP. The antioxidant properties of ginger could be attributed to its protecting components, which prevent DNA damage. Consequently, ginger could prevent apoptosis and improve the spermatogenesis and fertility (Zancan *et al.*, 2002; Miciński *et al.*, 2011). It could be concluded that ginger has a protective effect on DBP-induced reproductive toxicity in male rabbits to a certain extent.

Conflict of interest: The authors declare that there is no conflict of interests.

Acknowledgment: Grateful thanks to Professor Dr. Mahmoud M.A. Elmaghraby for statistical analysis.

REFERENCES

- Aghaie S., Nikzad H., Mahabadi J.A., Taghizadeh M., Azami-Tameh A., Taherian A., Sajjadian S.M., Kamani M. 2015. Protective effect of combined pumpkin seed and ginger extracts on sperm characteristics, biochemical parameters and epididymal histology in adult male rats treated with cyclophosphamide. *Anat. Sci. Int.*, 91: 382-390. <https://doi.org/10.1007/s12565-015-0314-x>
- Alam M.S., Ohsako S., Matsuwaki T., Zhu X.B., Tsunekawa N., Kanai Y., Sone H., Tohyama C., Kurohmaru M. 2010. Induction of spermatogenic cell apoptosis in prepubertal rat testes irrespective of testicular steroidogenesis: a possible estrogenic effect of di(n-butyl) phthalate. *Reproduction*, 139: 427-437.
- Baiomy A.A., Mansour A.A. 2015. Genetic and histopathological responses to cadmium toxicity in rabbit's kidney and liver: protection by ginger (*Zingiber officinale*). *Biol. Trace Elem. Res.* 170: 320-329. <https://doi.org/10.1007/s12011-015-0491-4>
- Bao A., Man X., Guo X., Dong H., Wang F., Sun H., Wang Y., Zhou Z., Sha J. 2011. Effects of di-n-butyl phthalate on male rat reproduction following pubertal exposure. *Asian J. Androl.*, 13: 702-709. <https://dx.doi.org/10.1038%2Faja.2011.76>
- Bearden H.J., Fuquay J. 1980. Applied Animal Reproduction. Reston, VA: Reston Publishing Co. Inc, 158-160.
- Borch J., Metzdrorf S.B., Vinggaard A.M., Brokken L., Dalgaard M. 2006. Mechanisms underlying the anti-androgenic effects of diethylhexyl phthalate in fetal rat testis. *Toxicology*, 223: 144-155. <https://dx.doi.org/10.1038%2Faja.2011.76>
- Bordbar H., Esmaeilpour T., Dehghani F., Panjehshahin M.R. 2013. Stereological study of the effect of ginger's alcoholic extract on the testis in busulfan-induced infertility in rats. *Iran J. Reprod. Med.*, 11: 467-472.
- Demetrius J.A. 1987. Testosterone in methods. In: Kaplan LA, editor. *Clinical chemistry tech AG. 2nd ed. CVMOS Co.*, p. 268.
- Doreswamy K., Shrilatha B., Rajeshkumar T., Muralidhara .2004. Nickel-induced oxidative stress in testes of mice: evidence of DNA damage and genotoxic effects. *J. Androl.*, 25: 996-1003. <https://doi.org/10.1002/j.1939-4640.2004.tb03173.x>
- El-Taieb M.A., Herwig R., Nada E.A., Greiberger J., Marberger M. 2009. Oxidative stress and epididymal sperm transport, motility and morphological defects. *Eur. J. Obstet. Gynecol. Reprod. Biol.*, 144: 199-203. <https://doi.org/10.1016/j.ejogrb.2009.02.018>
- Erkekoglu P., Rachidi W., Yuzugullu O.G., Giray B., Favier A., Ozturk M., Hincal F. 2010. Evaluation of cytotoxicity and oxidative DNA damaging effects of di(2-ethylhexyl)-phthalate (DEHP) and mono(2-ethylhexyl)-phthalate (MEHP) on MA-10 Leydig cells and protection by selenium. *Toxicol. Appl. Pharmacol.*, 248:52-62. <https://doi.org/10.1016/j.taap.2010.07.016>
- Farag A.G., Elhalwagy M.E., Farid H.E. 2010. Effect of ginger supplementation on developmental toxicity induced by fenitrothioninsecticide and/or lead in albino rats. *Pestic. Biochem. Physiol.*, 97: 267-274. <https://doi.org/10.1016/j.pestpb.2010.03.007>
- Farombi E.O., Abarikwu S.O., Adedara I.A., Oyeyemi M.O. 2007. Curcumin and kolaviron ameliorate di-n-butylphthalate-induced testicular damage in rats. *Basic Clin. Pharmacol. Toxicol.*, 100: 43-48. <https://doi.org/10.1111/j.1742-7843.2007.00005.x>
- Fukuoka M., Zhou Y., Tanaka A., Ikemoto I., Machida T. 1990. Mechanism of testicular atrophy induced by di-n-butyl phthalate in rats. Part 2. The effects on some testicular enzymes. *J. Appl. Toxicol.*, 10: 285-293. <https://doi.org/10.1002/jat.2550100410>
- Glombik K., Basta-Kaim A., Sikora-Polaczek M., Kubera M., Starowicz G., Styra J. 2014. Curcumin influences semen quality parameters and reverses the di(2-ethylhexyl)phthalate (DEHP)-induced testicular damage in mice. *Pharmacol. Rep.*, 66: 782-787. <https://doi.org/10.1016/j.pharep.2014.04.010>
- Graham P.R. 1973. Phthalate ester plasticizers: why and how they are used. *Environ. Health Perspect.*, 3: 3-12.
- Gray L.E. Jr, Wilson V.S., Stoker T., Lambright C., Furr J *et al.* 2006. Adverse effects of environmental antiandrogens and androgens on reproductive development in mammals. *Int. J. Androl.*, 29: 96-104. <https://doi.org/10.1111/j.1365-2605.2005.00636.x>

- Hafez D.A. 2010. Effect of extracts of ginger goots and cinnamon bark on fertility of male diabetic rats. *J. Am. Sci.*, 6: 940-947.
- Hosseinimehr S.J. 2014. Beneficial effects of natural products on cells during ionizing radiation. *Rev. Environ. Health*, 29: 341-353. <https://doi.org/10.1515/reveh-2014-0037>
- Kasahara E., Sato E.F., Miyoshi M., Konaka R., Hiramoto K., Sasaki J., Tokuda M., Nakano Y., Inoue Y. 2002. Role of oxidative stress in germ cell apoptosis induced by di (2-ethylhexyl) phthalate. *Biochem. J.*, 365: 849-856. <https://doi.org/10.1042/bj20020254>
- Khaki A., Fathiazad F., Nouri M., Khaki A.A., Chelar C., Ozanci S., Ghafari-Novin M., Hamadeh M. 2009. The effects of ginger on spermatogenesis and sperm parameters of rat. *Iran J. Reprod. Med.*, 7: 7-12.
- Kirtikar K.R., Basu B.D. 1991. Indian medicinal plants. 2nd ed., New Delhi India: *Periodical export*, 195-206.
- Kleymenova E., Swanson C., Boekelheide K., Gaido K.W. 2005. Exposure in utero to di(n-butyl) phthalate alters the vimentin cytoskeleton of fetal rat Sertoli cells and disrupts Sertoli cell-gonocyte contact. *Biol. Reprod.*, 73: 482-490. <https://doi.org/10.1095/biolreprod.104.037184>
- Kumar R., Gautam G., Gupta N.P. 2006. Drug therapy for idiopathic male infertility: rationale versus evidence. *J. Urol.*, 176: 1307-12. <https://doi.org/10.1016/j.juro.2006.06.006>
- Lioy P.J., Hauser R., Gennings C., Koch H.M., Mirkes P.E., Schwetz B.A., Kortenkamp A. 2015. Assessment of phthalates/phthalate alternatives in children's toys and childcare articles: Review of the report including conclusions and recommendation of the Chronic Hazard Advisory Panel of the Consumer Product Safety Commission. *J. Expo. Sci. Environ. Epidemiol.*, 25: 343-353. <https://doi.org/10.1038/jes.2015.33>
- Mahood I.K., Scott H.M., Brown R., Hallmark M., Walker M., Sharpe R.M. 2007. *In utero* exposure to di(n-butyl) phthalate and testicular dysgenesis: Comparison of fetal and adult end points and their dose sensitivity. *Environ. Health Perspect.*, 115: 55-61. <https://dx.doi.org/10.1289/ehp.9366>
- Mansour A.A., Salam M.A., Saad Y.M. 2012. Mice (*Mus musculus*) genome responses to methotrexate (MTX) and some plant extracts. *Life Sci. J.*, 9: 4881-4886.
- Marklund S., Marklund G. 1974. Involvement of the superoxide anion radical in the autooxidation of pyrogallol and a convenient assay for superoxide dismutase. *Eur. J. Biochem.*, 74: 469-474. <https://doi.org/10.1111/j.1432-1033.1974.tb03714.x>
- Matousek J. 1969. Effect on spermatogenesis in guinea pigs, rabbits and sheep after their immunization with sexual fluid of bulls. *J. Reprod. Fertil.*, 19: 63-72. <https://doi.org/10.1530/jrf.0.0190063>
- Micirński P., Pawlicki K., Wielgos E., Bochenek M., Gogol P., Ficek B. 2011. Total reactive antioxidant potential and DNA fragmentation index as fertility sperm parameters. *Reprod. Biol.*, 11: 135-144. [https://doi.org/10.1016/S1642-431X\(12\)60050-3](https://doi.org/10.1016/S1642-431X(12)60050-3)
- Mylchreest E., Wallace D.G., Cattley R.C., Foster P.M.D. 2000. Dose dependent alterations in androgen-regulated male reproductive development in rats exposed to Di (n-butyl) phthalate during late gestation. *Toxicol. Sci.*, 55: 143-151. <https://doi.org/10.1093/toxsci/55.1.143>
- Nair N. 2015. Dose-dependent short-term study of di-n-butyl phthalate on the testicular antioxidant system of Wistar rats. *Environ. Sci. Pollut. Res.*, 22: 2196-2204. <https://doi.org/10.1007/s11356-014-3457-8>
- Nair N., Bedwal S., Kumari D., Bedwal S., Bedwal R. 2008. Effect on histological and sperm kinetics in DBP exposed Wistar rats. *J. Environ. Biol.*, 29: 769-772.
- Niazi J.H., Prasad D.T., Karegoudar T.B. 2001. Initial degradation of dimethyl phthalate by esterases from *Bacillus* species. *FEMS Microbiol. Lett.*, 196: 201-205. <https://doi.org/10.1111/j.1574-6968.2001.tb10565.x>
- Noori S. 2012. An overview of oxidative stress and antioxidant defensive system. *Open Access Scientific Reports*, 1: 413. <https://doi.org/10.4172/scientificreports.413>
- O'Connor J.C., Frame S.R., Ladics G.S. 2002. Evaluation of a 15-day screening assay using intact male rats for identifying antiandrogens. *Toxicol. Sci.*, 69: 92-108. <https://doi.org/10.1093/toxsci/69.1.92>
- Oishi S., Hiraga K. 1980. Testicular atrophy induced by phthalic acid monoesters: effects of zinc and testosterone concentrations. *Toxicology*, 15: 197-202. [https://doi.org/10.1016/0300-483X\(80\)90053-0](https://doi.org/10.1016/0300-483X(80)90053-0)
- Paget G.E., Barnes J.M. 1964. Evaluation of drug activities, toxicity tests. pharmacometrics, vol. I. London and New York: Academic Press, 135.
- Paglia E., Valentine N. 1967. Studies on the quantitative and qualitative characterization of erythrocyte glutathione peroxidase. *J. Lab. Med.*, 70: 158-169.
- Pan G., Hanaoka T., Yoshimura M., Zhang S., Wang P., Tsukino H., Inoue K., Nakazawa H., Tsugane S., Takahashi K. 2006. Decreased serum free testosterone in workers exposed to high levels of di-n-butyl phthalate (DBP) and di-2-ethylhexyl phthalate (DEHP): a cross-sectional study in China. *Environ. Health Perspect.*, 114: 1643-1648. <https://dx.doi.org/10.1289/ehp.9016>
- Park J.D., Habeebu S.S.M., Klaassen C.D. 2002. Testicular toxicity of di(2-ethylhexyl) phthalate in young Sprague-Dawley rats. *Toxicology*, 171: 105-115. [https://doi.org/10.1016/S0300-483X\(01\)00567-4](https://doi.org/10.1016/S0300-483X(01)00567-4)
- Placer Z.A., Crushman L., Johnson B.C. 1966. Estimation of product of lipid peroxidation (malondialdehyde) in biochemical systems. *Anal. Biochem.*, 16: 359-364. [https://doi.org/10.1016/0003-2697\(66\)90167-9](https://doi.org/10.1016/0003-2697(66)90167-9)
- Rahmani A.H., Shabrimi F.M., Aly S.M. 2014. Active ingredients of ginger as potential candidates in the prevention and treatment of diseases via modulation of biological activities. *Int. J. Physiol. Pathophysiol. Pharmacol.*, 6: 125-136.
- Riaz F., Khan U.A., Ayub M., Shaukat S. 2011. Protective role of ginger on lead induced derangement in plasma testosterone and LH levels of male sprague dawley rats. *J. Ayub. Med. Coll. Abbottabad.*, 23: 24-27.
- Rihani L., Loukil B., Khelili K. 2015. Effect of dibutyl phthalate on sperm quality and liver injury in adult male rabbits. *American-Eurasian J. Toxicol. Sci.*, 7: 34-38.
- Sharma V., Boonen J., Chauhan N.S., Thakur M., De Spiegeleer B., Dixit V.K. 2011. *Spilanthes acmella* ethanolic flower extract: LC-MS alkylamide profiling and its effects on sexual behavior in male rats. *Phytomedicine*, 18: 1161-1169. <https://doi.org/10.1016/j.phymed.2011.06.001>
- Shultz V.D., Phillips S., Sar M., Foster P.M.D., Gaido K.W. 2001. Altered gene profiles in fetal rat testes after *in utero* exposure to di(n-butyl) phthalate. *Toxicol. Sci.*, 64: 233-242. <https://doi.org/10.1093/toxsci/64.2.233>
- Thompson C.J., Ross S.M., Gaido K.W. 2004. Di (n-butyl) phthalate impairs cholesterol transport and steroidogenesis in the fetal rat testis through a rapid and reversible mechanism. *Endocrinology*, 145: 1227-1237. <https://doi.org/10.1210/en.2003-1475>

- Thompson C.J., Ross S.M., Hensley J., Liu K., Heinze S.C. *et al.* 2005. Differential steroidogenic gene expression in the fetal adrenal gland versus the testis and rapid and dynamic response of the fetal testis to di(n-butyl) phthalate. *Biol. Reprod.*, 73: 908-917. <https://doi.org/10.1095/biolreprod.105.042382>
- Ünal S.G., Take G., Erdoğan D., Göktas G., Sahin E. 2016. The effect of di-n-butyl phthalate on testis and the potential protective effects of resveratrol. *Toxicol. Ind. Health*, 32: 1-14. <https://doi.org/10.1177/0748233713512364>
- Wang Y.B., Song L., Zhu Z.P. 2004. Effect of Dibutyl-Phthalate of the biochemical enzymes and lipid peroxidation in rat testes. *Natl. J. Androlog.*, 10: 729-733.
- Zahedi A., Khaki A., Ahmadi-Ashtiani H.R., Rastegar H., Rezazadeh Sh. 2010. *Zingiber officinale* Protective Effects on Gentamicin's Toxicity on Sperm in Rats. *J. Med. Plant.*, 9: 93-98.
- Zancan K.C., Marques M.O., Petenate A.J., Meireles M.A. 2002. Extraction of ginger (*Zingiber officinale* Roscoe) oleoresin with CO₂ and co-solvents: a study of the antioxidant action of the extracts. *J. Supercrit. Flu.*, 24: 57-76. [https://doi.org/10.1016/S0896-8446\(02\)00013-X](https://doi.org/10.1016/S0896-8446(02)00013-X)
- Zhou D., Wang H., Zhang J., Gao X., Zhao W., Zheng Y. 2010. Di-n-butyl phthalate (DBP) exposure induces oxidative damage in testes of adult rats. *Systems Biol. Reprod. Med.*, 56: 413-419. <http://dx.doi.org/10.3109/19396368.2010.509902>
-